



Original Article

Toxic Impact of Chlorpyrifos Insecticide on the Ovary of Pigeon (*Columba livia domestica*)

Shakeel Ahmed Memon^{1*}, Nasreen Memon² and Nadir Ali Birmani²

¹Department of Zoology, Government College University, Hyderabad, Pakistan

²Department of Zoology, University of Sindh, Jamshoro, Pakistan

ARTICLE INFO

Keywords:

Chlorpyrifos, Histological Examination, Ovaries, Pigeons

How to cite:

Memon, S. A., Memon, N., & Birmani, N. A. (2024). Toxic Impact of Chlorpyrifos Insecticide on the Ovary of Pigeon (*Columba livia domestica*): Chlorpyrifos Impact on Pigeon Ovary. MARKHOR (The Journal of Zoology), 5(01). <https://doi.org/10.54393/mjz.v5i01.96>

*Corresponding Author:

Shakeel Ahmed Memon
Department of Zoology, Government College University, Hyderabad, Pakistan
samemonn@gmail.com

Received Date: 11th February, 2024

Acceptance Date: 27th March, 2024

Published Date: 31st March, 2024

ABSTRACT

Modern agriculture and vector-borne diseases are responsible for the rapid increase in pesticide usage, which is harmful to animals, particularly birds. The declining in the diversity of bird's species is a major concern Chlorpyrifos (CPF) is the commonly used insecticide in agriculture sector. Unfortunately, CPF is still being applied across the world. **Objective:** To evaluate the toxic impact of chlorpyrifos on the ovaries of the pigeon in relation to the reproductive toxicity. **Methods:** For this purpose, N=80 healthy (*Columba Livia domestica*) pigeons were used. Pigeons had been acclimated for fifteen (15) days and divided into four equal groups (A-D) Oral dosages 1.3 mg, 1.6 mg, and 2.1 mg per kg body weight per day of chlorpyrifos (CPF) were administered respectively to group B, C and D for 84 consecutive days and pigeons from group (A) assigned as control. Daily observations were made on stress-related signs and behavioral changes. (H & E) staining method was applied to examine histological change in the ovary of pigeons after exposure to CPF, likewise for the control. **Results:** Birds from groups B-D displayed notable clinical signs such as: tremors, salivation, open-mouth breathing, ruffled feathers, lethargy and watery diarrhea and reduced food intake. The Histological examinations revealed that the ovary of pigeons from the B, C, and D showed notable variations such as follicular degeneration, vacuolation, hypertrophy, and fibrosis after exposure to CPF. The intensity was on high doses as compared to control which were with normal ovarian articulation small containing big follicles of all diameters. Oocytes, thecal layers, granulosa layers (g), stromal Tissue, and nucleus contained yolk-like secondary oocytes, mature follicles. **Conclusions:** In current study it was concluded that, the CPF produced drastic impact on the ovary of pigeon that may be associated with alterations in reproduction.

INTRODUCTION

The global usage of pesticide is increasing in agriculture sector to satisfy consumers' cravings for food, almost four million tons of pesticides were used worldwide, with Asian nations accounting for the majority (52.8%) of consumption and Pakistan is on second number in consumption in this region [1-3]. Chlorpyrifos (CPF) was originally developed to eradicate mosquitoes but CPF is now a versatile insecticide that is widely used in agriculture sector such as on cereals, cotton, fruits, nuts, vegetables, lawns, and ornamental plants [4]. CPF is commonly used inside home to efficiently control pests including cockroaches, fleas, spiders, and flies, even though it is predominantly used in agriculture [5]. In addition, it is used

locally to get rid of fleas and lice on domesticated animals and in dog kennels. Indiscriminate use of chlorpyrifos cause serious problems endangering the ecosystem since their residue lingers in the environment and continuously puts non-target living beings like birds at risk for health glitches [6, 7]. CPF's primarily toxic mechanism is Acetylcholinesterase (AChE) inhibition, resulting in muscarinic, bronchospasm, weakness, muscle fasciculation, and CNS symptoms such tremors, convulsions, anxiety, and coma are among the symptoms [8]. Synthetic insecticides like CPF, which are widely used, have the possible to harm development and reproduction. CPF affects the production of testosterone in animals and

decreases the release of pituitary hormones such FSH and LH [9]. According to reports, long term exposure of CPF have impact on reproductive system, which may result in sperm destruction, reduced semen quality, and changes in reproductive hormones [10] and at higher doses; these changes were also seen in total protein, liver enzymes, serum creatinine, as well as hematological and biochemical abnormalities [11]. The toxic effects of CPF on birds' liver, plasma and brain demonstrates inhibition of cholinesterase activities within two hours of exposure with symptoms, including gasping, salivation, feces, trembling, drooping wings, convulsions, recumbence, and death. [12]. The toxicological effects of OPs, such as chlorpyrifos, on hematology and serum biochemistry shows a significant drop in the values of erythrocytes, hemoglobin, and hematocrit in birds. Chicken treated with CPF results alterations in from serum biochemistry and histology of different organs including necrosis, hepatic hemorrhages and vacuolar disintegration of tubular epithelial cells' nephropathy. CPF also cause changes in hepatic sinusoids, alter fatty tissue, congest hepatic cells, and multiply bile duct cells. [13] Organophosphate (OP) insecticides, such as chlorpyrifos, demonstrates their toxicity by preventing the nervous system's production of AChE, a crucial neurotransmitter in the central and peripheral nervous systems [14, 15].

This study was aimed to evaluate the harmful effects of chlorpyrifos on avian female reproductive organs and to gather data on the indiscriminate use of pesticides that result in the extinction of important bird species and a decline in avifaunal biodiversity.

METHODS

Experiment Design and Birds

The ovarian toxicity of chlorpyrifos pesticide was tested in 80 healthy female adult pigeons (*Columba livia domestica*). Before the experiment, all pigeons were vaccinated and acclimatized in a lab for 15 days. They lived in tidy wooden wire cages. Pigeons ate grains and seeds and drank clean water. After acclimation, they were placed into four equal groups of twenty pigeons (A, B, C, and D) and housed in various cages by tagging method. Their pre-test weights were recorded. Pigeons from groups B, C, and D were treated with CPF insecticide, whereas group A was the control.

Preparations for Insecticide and the Study Protocol

Toxicological methods determined the pesticide concentration (Chlorpyrifos 40EC) via LD50. Groups A, B, C, and D received oral treatment at 1/25th, 1/20th, and 1/15th of the LD50 (1.3 mg, 1.6 mg, and 2.1 mg/kg body weight/day) with one milliliter of maize oil for 84 days, while pigeons from A group acted as controls. The current study fed all pigeons the same amount of grains and seeds, 22% crude

proteins, and water.

Observation of Body Weights, Food Intake, and Clinical Signs The Histological Techniques

Daily observations were made on clinical and stress-related signs, symptoms, and behavioral changes based on LD50 of CPF technical information during the trial with a continuous observations on daily basis for their physical activates after doses administrated. And frequency of main only main clinical signs is shown in table form. Histology, body and organ weights and food consumption were assessed. After the experiment, eight pigeons from each group were randomly dissected and weighed. Absolute and relative ovarian in table form weights were recorded. For 24–48 hours, ovaries were immersed in Bouin's solution to analyses histological changes. Small ovary fragments were incorporated in paraffin wax after drying in an alcohol-graded series. Thin tissue slices (5–6 μ m) were cut using a Rotary microtome and stained with Harris's hematoxylin (Gurr, 1956) and Eosin (Putt, 1948). Microphotography and histology studies were done using the Best Scope LCD digital biological LCD microscope BLM 260.

Statistics Analysis

One-way analysis of variance (ANOVA) was used to evaluate the data. Significant values were determined as Mean \pm SD at the ($P < 0.05$), ($P < 0.01$), and ($P < 0.001$) levels. The least significant difference (LSD) test was used to assess the mean difference between the groups using the statistical program Statistics 8.1.

RESULTS

The following is the presentation of the study's findings about the toxicity of chlorpyrifos pesticide to exposed birds at various doses. The widespread toxicity of chlorpyrifos, a commonly used organophosphate pesticide has shown toxic effects on the reproductive systems of birds.

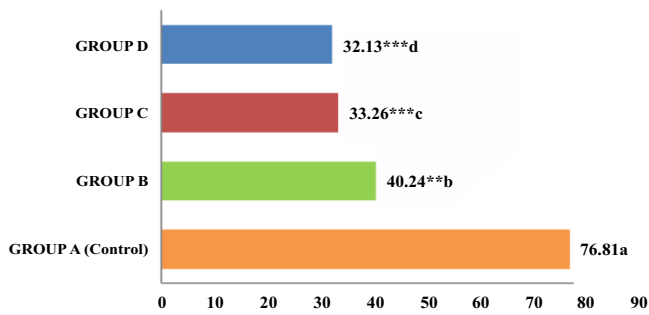
Clinical Observation and Feed Intake

During the trial, pigeon from groups B, C, and D showed symptoms. Tremors, lethargic or not moving, depressed and remained isolated and diarrhea (Table 1), after exposure to CPF open mouth breathing, salivation, tremors, and motor activity, isolation, watery diarrhea and decreased mating frequency due to not coupling with male pigeons were present in same cages. In comparison, the control birds were healthy. Group D birds were dangerous. CPF-exposed birds showed behavioral changes from the first week of treatment, including a substantial decrease in feed consumption compared to the control group.

Table 1: The Frequency of Clinical Signs Observed in Pigeons from Group B-D Exposed to Chlorpyrifos Insecticide

Clinical Signs	Percentage (%)
Tremors	60 %
Lethargy or Not Active	40%
Depressed or Isolated	40%
Diarrhea	30%
Others	20%

Exposures to CPF exhibited highly significant ($P^{**} < 0.01$) ($P^{***} < 0.01$) reduction in feed intake in each pigeon from group B, C, D, in comparison with daily feed intake of each pigeon from control group (A) The Mean values are in Figure 1. Six birds in Group B, eight in Group C, and ten in Group D died from CPF toxicity in the second to sixth week of treatment. No birds in the control group died.

Mean Group wise Feed intake in grams**Figure 1:** Comparison of Daily Feed Intake (grams per day) in Pigeons: Control (Group A) vs. Chlorpyrifos Exposed Groups (Groups B, C, and D)

Effects on Absolute Body and Organ Weight Body Weights

The body weight of treated birds in the B, C, and D groups were significantly influenced by CPF exposure. Birds in groups B, C, and D had significantly lower body weights ($P < 0.05$) compared to the control group, with a considerable decline ($P < 0.01$) in birds of groups C and D. Each group's birds' body weight was recorded every fortnightly. All treatment groups' weight losses were recorded throughout the study. The pigeons on insecticide chlorpyrifos exposure reduced birds' body when compared their body weights from on the end of trail and with control group. At the end of experimental study, the control group's body weight significantly higher than groups B, C and D's (Table 2).

Table 2: The Fortnightly Body Weights of the Birds Exposed to Chlorpyrifos Insecticide as Compared to the Control Group

Days	Control A	Group B	Group C	Group D
Day 1	277	276	274	276
Day 14	288	270.33	268	260
Day 28	295	263.3	260	243
Day 42	313	257	248	229
Day 56	324	250	241	221
Day 72	330	247	229	215
Day 84	344	240	220	207

Absolute and Relative weights of the Ovary

Total and relative ovary weights the female pigeons were dissected and their ovaries weighed after the procedure. Table 3 shows that chlorpyrifos therapy lowered ovarian size and weight compared to the control group. Compared to the control group, chlorpyrifos insecticides significantly affected ovarian weights ($P < 0.01$) in birds from groups B, C, and D. Post-treatment gonado-somatic index and relative ovarian weights for all treatment groups were considerably ($P < 0.01$) lower than the control group (Table 3).

Table 3: Ovarian weight (Absolute) and relative gonad-somatic index in Chlorpyrifos-treated birds of treated groups B₁ to D₁ with a significant increase ($P < 0.01$)** and *** as compared to group A₁ Mean Values not sharing the same letters are significantly different from each other

Parameters	Absolute and Relative Ovarian Weight (Mean \pm SD)			
	Group (A) Control	Group B	Group C	Group D
Ovarian Weight	3.30 \pm 0.03 ^a	2.1 \pm 0.02 ^{***b}	1.70 \pm 0.02 ^{***c}	1.40 \pm 0.01 ^{***d}
Relative Ovarian Weight	0.95 \pm 0.02 ^a	0.87 \pm 0.02 ^{***b}	0.70 \pm 0.01 ^{***c}	0.67 \pm 0.01 ^{***cd}

The Impact of Chlorpyrifos Insecticides on the Ovarian Health of Treated Avian Species Ovaries General and Morphological Observations

Birds' single functional left ovary contains a columnar epithelium with numerous cortical follicles of various sizes and shapes. Blood vessels were visible in the control group birds' yolky ovum. All treated birds' ovaries had tiny, translucent, white bubbles that resembled follicles in groups B, C, and D. The control birds' ovaries had healthy, yolky follicles of various sizes.

Histology of Chlorpyrifos Insecticide-Exposure and Control Ovaries

The control group ovaries had healthy, large and small follicles with intact granulosa membranes. Microscopic images of control birds' ovaries revealed all diameters of healthy follicles, follicular epithelium thickness (including granulosa and theca cells), and maturation differed (Figure 2).

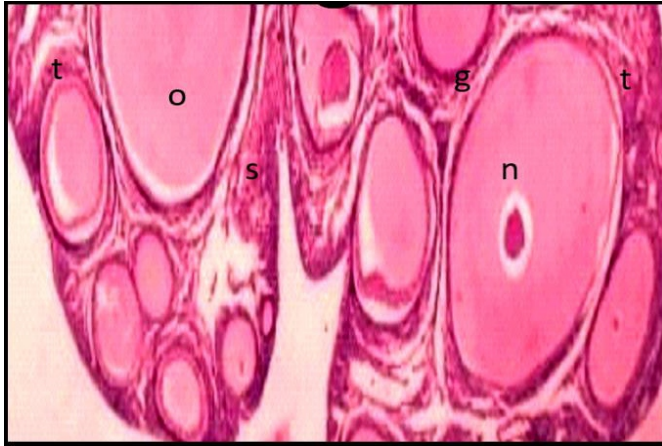


Figure 2: Microphotography Section of the Ovary of the Control Group

Microphotography of the Control group pigeon's ovary shows small and big follicles of all diameters. Oocytes (o), thecal layers (t), granulosa layers (g), stromal Tissue (s), and the nucleus (n) contain yolk-like secondary oocytes, mature follicles, and little yellow follicles (Primary oocytes) H&E. X20.

Histological analysis of group B's ovary showed (Figure 3) that the follicles had degenerated and were beginning to burst the columi.

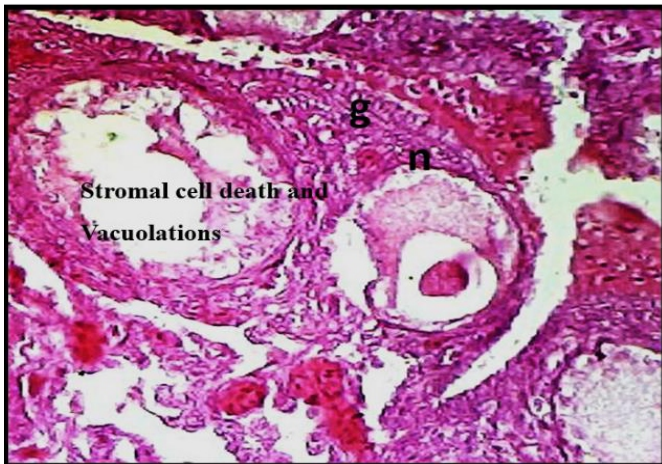


Figure 3: Microphotography Shows One Secondary Oocyte-Containing Follicle in Group B Pigeon's Ovary

Large follicles are decayed. Stromal cell death, stoma enlargement, and vacuolation regress the follicle's connective tissue. The H&E 40X.

A few small follicles and one secondary oocyte were observed. Fibrosis and hypertrophy were found in Pigeon's ovaries' Group C stromal cells. Large follicles were empty (Figure 4).

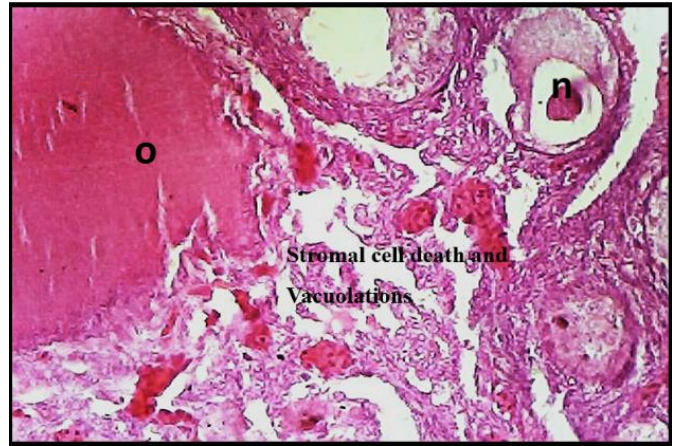


Figure 4: In ovary group C, microphotography showed a simple epithelial membrane of follicles rupturing and destroying chromatin. Degenerate follicles, bloody hypertrophy or fibrosis, non-growing primary follicles, and stromal vacuolation are apparent in the photograph. forty from H&E. 40X.

Stomas vacuolate, stromal cells grow, and connective tissue shrinks during ovulation. Group C pigeons have broken chromatin in their ovarian simple columnar surface epithelium. Group D ovaries have stromal vacuolation (Fig.5). Few nerves, connective tissue, and stromal cells found in the D group's ovary. Isolating the follicle ruptured granulosa cells resembling a primordial oocyte. Group D ovarian images showed stalks stoma with complete vacuolation and no connective, nerve, or vascular tissue centers and no mature follicles. The group D birds lack ovarian follicular stages. Groups B, C, and D birds have drastically altered their ovaries and female reproductive organs due to chlorpyrifos chemical exposure. Ecological toxicology research on chlorpyrifos' effects on domestic pigeon ovaries is ongoing. Chlorpyrifos heavily damaged the ovaries, which produce eggs and sustain reproductive health. New information shows that pesticide use on bird populations must be studied and safeguarded to reduce its negative effects on biodiversity and animal health.

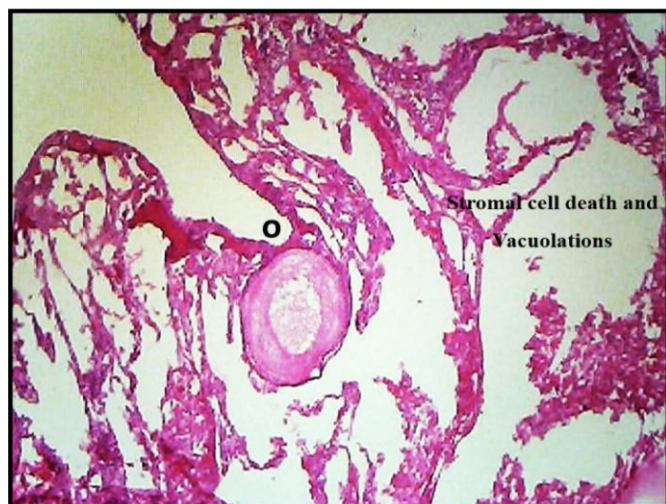

Figure 5: The Ovary of D group pigeons contains single primary follicle oocyte and mature follicles were absent in this image and stroma with full vacuolation without connective, nervous, and vascular tissue.

DISCUSSION

Our study showed that, the birds without treatment were healthy and active, with no clinical problems while birds treated with higher chlorpyrifos doses displayed mild to severe clinical indications as tremors, diarrhea, dullness, stumbling gait, and reduced crowing. On other hand chickens fed chlorpyrifos shows these same results in accordance with our results [16-18]. In our investigation, chlorpyrifos caused cholinergic toxicity. All subjected birds had signs of behavioral changes not interested to feed intake similarly to previous evidences [19-21]. In our study the pigeon's treated with chlorpyrifos exhibited significant declines in body weight and feed deficiency in pigeons from group B-D, which was contrary to the results of the previous investigation [22]. Furthermore, the treated birds with high dose CPF exposure displayed clinical signs as dullness, and decreased appetite for food in pigeons from group C and D. The earlier studies found no statistically significant body weight or feed efficiency decreases in chlorpyrifos-treated birds. In birds, sub-lethal pesticide exposure caused lethargy, depression, and decreased food consumption [23, 24]. Whereas same with CPF exposure reduced hatch rates and increased infant deformities. No changes were made to newborn chick body or brain weights by CPF. Oral CPF at 55 mg/kg body weight may improve layers [25-28]. The adverse effects of chlorpyrifos first were mild but worsened. The metabolites of chlorpyrifos cause neurotoxicity and tissue damage [29, 30]. Therefore, CPF inhibits acetyl cholinesterase (AChE), which stops neurotransmission at cholinergic synapses

[31, 32]. Pathos-morphological studies assessed organ weights and shapes, while histopathological studies showed pesticide damage to vital organs and tissues [33]. Critical evaluations of organophosphate pesticide impact on avian systems reveal population turnover may affect pesticide-induced adult mortality, reduced fecundity, and partial sterility [34]. Our results were also in accordance with reported results wherein mortality was recorded due to the toxicity of CPF in pigeons of group B, C and D. Since wild birds only reach sexual maturity once a year, these two factors may dramatically impact their population [35]. OP such as CPF pesticides influence almost every bodily function, therefore long-term exposures may affect demographics and ecology [36]. Female quail with 100 ppm parathion on day 10 have considerably lower plasma progesterone, corticosterone, and luteinizing hormone than those with 0 or 25 ppm [37]. Short-term parathion use disrupts steroid hormones, producing reproductive issues in quail [38]. In present study compared to birds in the control group, the toxic effects of chlorpyrifos insecticides on ovarian weights were very significant, birds belonging to groups B, C, and D. CPF-treated birds had less number of large follicles, damaged and degraded follicles in their ovaries. Ovarian architecture, follicle size, and maturity were normal in control birds. The dose-dependent damage to stromal cells induced hypertrophy, vacuolation, and connective tissue regressing follicles and eggs has been studied in ecological theory and practice in birds [39]. In current study CPF produced follicular deterioration where just one follicle (secondary oocytes) and a few tiny follicles were visible in the ovary of the pigeon belonging to group B. Group C, pigeon's ovaries showed severe alterations in the stroma cells, including fibrosis and hypertrophy, vacuolation in stomas, stromal cell hypertrophy and connective tissue regressing follicles. In the ovary of group D, stromal vacuolation is clearly visible connective tissue, and stromal cells damage. These observations revealed that birds of groups B, C, and D had significantly altered ovaries and female reproductive organ system as a result of exposure to chlorpyrifos insecticides. Same results reported that complex network of physiological reactions is being discovered by studying chlorpyrifos' effects on pigeon ovaries, demonstrating bird reproductive systems' vulnerability to human toxins [40]. Current study highlighted ecological stewardship to conserve ecosystems and the need for tougher pesticide controls to protect animals. So, this new study will demonstrate the need for coordinated bird population and biodiversity

protection in pesticide-heavy environments.

CONCLUSIONS

In our study the results revealed that, synthetic insecticide like CPF produced significant alteration in the body and ovarian weights, feeding habits, exerted clinical sign and histopathological profiles of ovary. Exposure to CPF produced severe impacts on pigeons' reproductive organ. The Pigeon's ovary exhibited follicular degeneration, vacuolation, hypertrophy, and fibrosis. These effects of CPF toxicity also proved impact on cellular level through distinctive histopathology on different doses exposure.

Authors Contribution

Conceptualization: SAM

Methodology: SAM

Formal analysis: SAM

Writing, review and editing: NAB, NM

All authors have read and agreed to the published version of the manuscript.

Conflicts of Interest

The authors declare no conflict of interest.

Source of Funding

The author received no financial support for the research, authorship and/or publication of this article.

REFERENCES

- [1] Zhang W, Jiang F, Ou J. Global pesticide consumption and pollution: with China as a focus. *Proceedings of The International Academy of Ecology and Environmental Sciences*. 2011 Aug; 1(2): 125.
- [2] Daly HV, Doyen JT, Ehrlich PR. *Introduction to Insect Biology and Diversity*. 1978.
- [3] Khan MA, Iqbal M, Ahmad I, Soomro MH, Chaudhary MA. Economic evaluation of pesticide use externalities in the cotton zones of Punjab, Pakistan. *The Pakistan Development Review*. 2002 Dec: 683-98. doi: 10.30541/v41i4lpp.683-698.
- [4] Aktar W, Sengupta D, Chowdhury A. Impact of pesticides use in agriculture: their benefits and hazards. *Interdisciplinary Toxicology*. 2009 Mar; 2(1):1-2. doi: 10.2478/v10102-009-0001-7.
- [5] Al-Saleh IA. Pesticides: A Review Article. *Journal of Environmental Pathology, Toxicology and Oncology: Official Organ Of The International Society For Environmental Toxicology And Cancer*. 1994 Jan; 13(3):151-61.
- [6] Khan MI, Shoukat MA, Cheema SA, Arif HN, Niazi NK, Azam M et al. Use, contamination and exposure of pesticides in Pakistan: A Review. *Pakistan Journal of Agricultural Sciences*. 2020 Jan; 57(1).
- [7] Waheed S, Halsall C, Sweetman AJ, Jones KC, Malik RN. Pesticides contaminated dust exposure, risk diagnosis and exposure markers in occupational and residential settings of Lahore, Pakistan. *Environmental Toxicology and Pharmacology*. 2017 Dec; 56: 375-82. doi: 10.1016/j.etap.2017.11.003.
- [8] Khaleghizadeh A, Roselaar K, Scott DA, Tohidifar M, Blair M, Mlíkovský J. *Birds of Iran: Annotated checklist of the species and subspecies*. Tehran: Iranshenasi Publishing; 2017.
- [9] Cooper JE. The role of birds in sustainable food production. *Biodiversity & Conservation*. 1995 Apr; 4: 266-80. doi: 10.1007/BF00055973.
- [10] Ledere R. *Medicinal Uses of Birds*. 2015. [Last cited: 04th April 2024]. Available at: <http://ornithology.com/medicinaluses-of-birds>.
- [11] Adam AV. *International code of conduct on the distribution and use of pesticides*. 1987.
- [12] Bolognesi C. Genotoxicity of pesticides: A Review of Human Biomonitoring Studies. *Mutation Research/Reviews in Mutation Research*. 2003 Jun; 543(3): 251-72. doi:10.1016/S1383-5742(03)00015-2.
- [13] Goldman LR. Managing pesticide chronic health risks: US policies. *Journal of Agromedicine*. 2007 Jul; 12(1): 67-75. doi: 10.1300/J096v12n01_07.
- [14] Lernoud J, Willer H, Kilcher L. *The world of organic agriculture. Statistics and Emerging Trends*. 2016: 23-4.
- [15] Pelaez V, da Silva LR, Araujo EB. Regulation of Pesticides: A Comparative Analysis. *Science and Public Policy*. 2013 Oct 1; 40(5): 644-56. doi:10.1093/scipol/sct020.
- [16] Slotkin TA, Seidler FJ, Fumagalli F. Exposure to organophosphates reduces the expression of neurotrophic factors in neonatal rat brain regions: similarities and differences in the effects of chlorpyrifos and diazinon on the fibroblast growth factor superfamily. *Environmental Health Perspectives*. 2007 Jun; 115(6): 909-16. doi: 10.1289/ehp.9901.
- [17] Eaton DL, Daroff RB, Autrup H, Bridges J, Buffler P, Costa LG et al. Review of the toxicology of chlorpyrifos with an emphasis on human exposure and neurodevelopment. *Critical reviews in toxicology*. 2008 Jan; 38(2): 1-25. doi: 10.1080/10408440802272158.
- [18] Suliman, Khan A, Shah SS, Gulfam N, Khisroon M, Zahoor M. Toxicity evaluation of pesticide chlorpyrifos in male Japanese quails (*Coturnix japonica*). *Environmental Science and Pollution Research*. 2020 Jul; 27: 25353-62. doi: 10.1007/s11356-020-08953-4.

- [19] Trijau M, Goussen B, Brain R, Maul J, Galic N. Development of a mechanistic model for analyzing avian reproduction data for pesticide risk assessment. *Environmental Pollution*. 2023 Jun; 327: 121477.
- [20] Kamrin MA. *Pesticide profiles: toxicity, environmental impact, and fate*. CRC Press; 1997. doi: 10.1201/9781420049220.
- [21] Slotkin TA, Seidler FJ, Ryde IT, Yanai J. Developmental neurotoxic effects of chlorpyrifos on acetylcholine and serotonin pathways in an avian model. *Neurotoxicology and Teratology*. 2008 Sep; 30(5): 433-9. doi: 10.1016/j.ntt.2008.02.005.
- [22] Kammon AM, Brar RS, Sodhi S, Banga HS, Nagra NS, Singh J. Ameliorating effect of vitamin C on immunological implications induced by chronic chlorpyrifos toxicity in broilers. *Libyan Veterinary Medical Journal*. 2010; 1: 164-80.
- [23] Henna Wani HW, Shafiqur Rahman SR, Shagufta Azmi SA, Sahil Dutta SD, Maneesh Sharma MS. Effect of chlorpyrifos toxicity on growth parameters in broiler chickens. 2015.
- [24] Young H. A consideration of insecticide effects on hypothetical avian populations. *Ecology*. 1968 Sep; 49(5): 991-4. doi: 10.2307/1936550.
- [25] Fontaine R, Neves VC, Rodrigues TM, Fonseca A, Gonçalves D. The breeding biology of the endemic Azores Woodpigeon *Columba palumbus azorica*. *Ardea*. 2019 May; 107(1): 47-60. doi: 10.5253/arde.v107i1.a4.
- [26] Greaves AK, Letcher RJ. A review of organophosphate esters in the environment from biological effects to distribution and fate. *Bulletin of Environmental Contamination and Toxicology*. 2017 Jan; 98:2-7. doi: 10.1007/s00128-016-1898-0.
- [27] Raley-Susman KM. Like a Canary in the coal mine: behavioral change as an early warning sign of neurotoxicological damage. *Pesticides-Toxic Aspects*, Rijeka, InTech. 2014 Feb: 135-62.
- [28] Grue CE, Gibert PL, Seeley ME. Neurophysiological and behavioral changes in non-target wildlife exposed to organophosphate and carbamate pesticides: thermoregulation, food consumption, and reproduction. *American Zoologist*. 1997 Sep; 37(4): 369-88. doi: 10.1093/icb/37.4.369.
- [29] Grue CE, Hart AD, Mineau P. Biological consequences of depressed brain cholinesterase activity in wildlife. 1991.
- [30] Rattner BA, Sileo L, Scanes CG. Oviposition and the plasma concentrations of LH, progesterone and corticosterone in bobwhite quail (*Colinus virginianus*) fed parathion. *Reproduction*. 1982 Sep; 66(1): 147-55. doi: 10.1530/jrf.0.0660147.
- [31] Rattner BA, Sileo L, Scanes CG. Hormonal responses and tolerance to cold of female quail following parathion ingestion. *Pesticide Biochemistry and Physiology*. 1982 Aug; 18(1): 132-8. doi: 10.1016/0048-3575(82)90096-7.
- [32] Rattner BA, Clarke RN, Ottinger MA. Depression of plasma luteinizing hormone concentration in quail by the anticholinesterase insecticide parathion. *Comparative Biochemistry and Physiology Part C: Comparative Pharmacology*. 1986 Jan; 83(2): 451-3. doi: 10.1016/0742-8413(86)90153-2.
- [33] Schom CB, Abbott UK, Walker N. Organophosphorus pesticide effects on domestic and game bird species: Dursban.
- [34] Gile JD and Meyers SM. Effect of adult mallard age on avian reproductive tests. *Archives of environmental contamination and toxicology*. 1986 Nov; 15: 751-5. doi:10.1007/BF01054922.
- [35] Gupta RC, editor. *Veterinary toxicology: basic and clinical principles*. Academic press; 2012.
- [36] Mohammad F, Al-Badrany Y, Al-Jobory M. Acute toxicity and cholinesterase inhibition in chicks dosed orally with organophosphate insecticides. *Archives of Industrial Hygiene and Toxicology*. 2008 Sep; 59(3): 145-51. doi: 10.2478/10004-1254-59-2008-1873.
- [37] Malik G, Dahiya JP, Gera S. Biochemical studies on Chlorpyrifos toxicity in broiler chickens. *The Indian Journal of Animal Sciences*. 2004 May; 74(5).
- [38] Bharathi P, Reddy AG, Kalakumar B, Madhuri D. Experimental evaluation of certain herbs against chlorpyrifos-induced oxidative stress and toxicity in poultry. *Indian Journal of Animal Sciences* 2010 Feb; 80: 94-8.
- [39] Buriro SA, Birman NA, Shaikh AM. 96. New trematode *Psilochasmus platyrhynchos* (Trematode: Psilochasmidae) from Mallard *Anas platyrhynchos* (Anseriformes: Anatidae) in Sindh province of Pakistan. *Pure and Applied Biology (PAB)*. 2020 Feb; 9(1): 1025-30. doi: 10.19045/bspab.2020.90107
- [40] Birmani NA, Buriro SA, Shaikh AM, Dharejo AM. A new Notocotylid trematode *Paramonostomum bagoderoi* n. sp. (Trematoda: Notocotylidae) in Mallard *Anas platyrhynchos* (Anseriformes: Anatidae) in Sindh, Pakistan. *International Journal of Advanced Research in Biological Sciences*. 2016; 3: 130-5.