



MARKHOR

THE JOURNAL OF ZOOLOGY

<https://www.markhorjournal.com/index.php/mjz>

ISSN (P): 2790-4377, (E): 2790-4385

Volume 5, Issue 1 (Jan-Mar 2024)



Original Article

Biometrical Analysis of the Indian One Horned Rhinoceros (*Rhinoceros unicornis*) in Laal Suhanra National Park, Pakistan

Muhammad Rizwan Khan¹, Bushra Nisar Khan², Zia Ullah³, Fakhra Nazir⁴, Arshia Mukhtar², Mubasher Rauf⁵, Muhammad Azhar¹, Abida Mushtaque⁶, Rida Fatima⁷

¹Safari Zoo, Punjab Wildlife and Parks Department, Lahore, Pakistan

²Institute of Zoology, University of the Punjab, Lahore, Pakistan

³Department of Small Animal Clinical Sciences, University of Veterinary and Animal Sciences, Lahore, Pakistan

⁴Capital University of Science and Technology, Islamabad, Pakistan

⁵Department of Pathology, Cholistan University of Veterinary and Animal Sciences, Bahawalpur, Pakistan

⁶Center of Excellence in Molecular Biology, University of the Punjab, Lahore, Pakistan

⁷University of Veterinary and Animal Sciences, Lahore, Pakistan

ARTICLE INFO

Keywords:

Biometrical Analysis, One-Horned Rhinoceros, Megaherbivores, Necropsy, Threatened Species

How to cite:

Khan, M. R., Nisar Khan, B., Ullah, Z., Nazir, F., Mukhtar, A., Rauf, M., Azhar, M., Mushtaque, A., & Fatima, R. (2024). Biometrical Analysis of the Indian One Horned Rhinoceros (*Rhinoceros unicornis*) in Laal Suhanra National Park, Pakistan: Biometrical Analysis of the Indian One Horned Rhinoceros. MARKHOR (The Journal of Zoology), 5(01). <https://doi.org/10.54393/mjz.v5i01.93>

*Corresponding Author:

Bushra Nisar Khan
Conservation Biology Lab, Institute of Zoology,
University of the Punjab, Lahore, Pakistan
bushra.zool@pu.edu.pk

Received Date: 11th February, 2024

Acceptance Date: 27th March, 2023

Published Date: 31st March, 2024

ABSTRACT

The Indian One-Horned Rhinoceros (*Rhinoceros unicornis*), commonly referred to as the Indian Rhinoceros, is an endangered species inhabiting the floodplains and grasslands of the Indian subcontinent. Once abundant, the species now faces a vulnerable status in its homeland, as confirmed by the International Union for The Conservation of Nature IUCN's assessment.

Objective: To record *Rhinoceros unicornis*' biometric body measurements for the first time.

Methods: The following study delves into the significance of body biometry data for the conservation of this remarkable species Indian One Horned Rhinoceros housed at Lal Suhanra National Park, Punjab, Pakistan. In order to give conservationists, the resources they need to develop more effective methods involving habitat management, population monitoring, and captive breeding programs, a thorough analysis of the physical characteristics, growth trends, and sexual dimorphism of 42-year-old Indian Rhinos via the evaluation of the body measurements was conducted. **Results:** This study presents comprehensive body measurements of the Indian One-Horned Rhinoceros which have never been published before. The length of the rhino itself spanned 143 inches, encapsulating the magnitude of this magnificent creature. These insightful observations are crucial for protecting the threatened species, particularly considering the growing threats caused by habitat loss, poaching, and the effects of climate change. **Conclusions:** Biometric analysis of large mammals assumes a pivotal role when designing enclosures and estimating the enclosure dimensions.

INTRODUCTION

Megaherbivores are endangered around the world scale due to increasing threats of habitat loss, fragmentation, and poaching to meet the demand for their body parts which is prohibited yet still practiced illegally [1]. The majority of these endangered species' populations are kept in remote protected regions. Out of the five rhinoceros' species, the Greater One Horned Rhinoceros (*Rhinoceros unicornis*) is the second largest and the fourth largest terrestrial mammal [2]. The vast grasslands and riverine

woods that provide constant access to water and greenery are the habitats to the Indian rhinoceros [3]. The one-horned rhinoceros (*Rhinoceros unicornis*, *GOH-rhino*) is presently the least threatened of the three nevertheless-existing Asian rhinoceros' species. It can be found in seven Indian national Parks and flora and fauna Sanctuaries, as well as in two national Parks and one wildlife Sanctuary in Nepal [4]. Consistent with the worldwide Union for Conservation of Nature and herbal sources (IUCN), the

population within the wild is classed as “prone” and with cutting-edge numbers ranging around 3,400, it is still far from a “near threatened” status. Rhinos constitute examples of species in which upgrades of the control of *ex-situ* populations are important components of the general preservation efforts [5,6]. These enormous creatures used to roam the flood plains of northwest Burma, the Gangetic Plain, and the Indus River Valley in northern Pakistan throughout historical times, beginning around 1400 AD. But since the seventeenth century, habitat fragmentation and hunting have endangered this species everywhere, in the Chitwan Valley, lowland Bhutan, the Teesta Valley in West Bengal, and the Brahmaputra Valley in Assam [2]. The Indian rhinoceros is particularly important for conservation [3]. Similar to other alluring large herbivores, rhinoceros require large territory to support thriving population. They take on the function of umbrella species, encapsulating the conservation requirements for both themselves and a wider range of smaller cohabiting species since they serve as one of the core species within their ecosystems [4,7]. This once-abundant rhino population today faces a variety of challenges, the most significant of which is rhino horn poaching for its valued horn [8]. This species was classified as vulnerable by the IUCN [3]. Important concerns about identifying species, comprehending ecology can be resolved using biometric analysis. Furthermore, these data are crucial for monitoring population trends and conservation efforts. Biometric analysis is extremely significant to zooarcheologists [9]. Body dimensions and proportions are important for creating cages for zoo animals. These dimensions include length, width, height, and angular measurements [3]. Situated in seven protected zones in India, approximately 83% of the world's wild one-horned rhino population may be found. An in-depth analysis of these populations' evolutionary history and genetic makeup would be important for putting the reintroduction-based conservation measures that have been suggested recently for the species into practice [10].

The goal of the current study was to record this significant species' biometric body measurements for the first time. Detailed measurements of the Indian One-Horned Rhino's body dimensions, including height, girth, ear length, nail dimensions, measurements of the foot pads, skin thickness at various body parts, thickness of abdominal fat, and measurements of several essential organs, are among the analysis's main findings. Since these measurements have never been documented before, this study was absolutely critical to the preservation of these massive herbivores.

METHODS

The greater one-horned rhinoceros is a unique animal that is mostly found in tall grasses of floodplains, riverine woodlands and rarely found in hills [5] (figure 1). Two rhinoceros that were housed at Laal Suhanra National Park close to Bahawalpur were gifted to Pakistan by the king of Nepal in 1982. These rhinos were housed in an enormous enclosure spanning more than 153,000 acres in Laal Suhanra, Punjab, Pakistan, which is home to this endangered species. Being protected, the park is an essential stronghold for the protection of this endangered species, protecting it from habitat degradation and hunting. The necropsy investigation of the rhinoceros revealed that it had separation anxiety before it died, which was probably caused by the death of its companion from tuberculosis. Since 1982, the two had lived together. According to historical records, the rhinoceros was receiving medical attention for a health issue that began on February 11, 2019. On the morning of February 22, 2019, the animal died despite receiving medical care. An expert team was summoned to examine the animal after it had died.



Figure 1: Indian One Horned Rhinoceros at Lal Suhanra National Park, Punjab, Pakistan (Source: @abuzarmir, tribune.com.pk)

1. Midline Approach (Ventro-dorsal Approach): To access the body cavities and organs, a longitudinal incision is made along the animal's midline, from the neck or head to the tail.
2. Lateral Approach (Lateral Recumbency): This method involves placing the animal on its side in lateral recumbency and making an incision along the body's lateral aspect.
3. Dorsal Approach (Dorsal Recumbency): The animal is positioned on its back in a dorsal recumbent position, and the dorsal portion of the body is incised [11-13].

Midline approach was used in this particular case. The abdominal and thoracic cavities can be accessed with this method. The major organ systems, such as the heart, lungs, liver, kidneys, and gastrointestinal tract, can all be thoroughly examined employing the methods Christiansen; Campione and Evans [12,14]. First, a skin incision was made, and the thickness of the skin-including the layer of fat beneath it-was measured. Then the abdominal cavity was opened, and then the thoracic cavity, with the use of instruments like an ax, saw, and hammer. After being removed, each organ was measured individually. The nomenclature for the skin folds and body regions for greater one-horned rhinoceros used to assess the body condition are shown in figure 2.

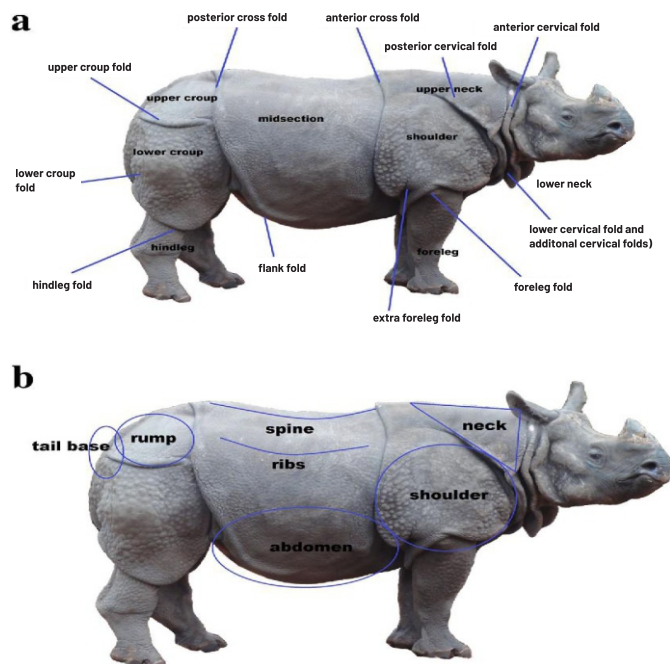


Figure 2: a) The Nomenclature for the Skin Folds and Body Regions for Greater One-Horned Rhinoceros (*Rhinoceros Unicornis*) b) The Body Regions Used to Assess the Body Condition [15].

RESULTS

The length of the rhino measured a total of 143 inches (363.22 cm), giving an idea of the magnitude of this megaherbivore.

Forequarters

34 inches (86.36 cm) was the length of the shoulder measured from the withers to the caudal part of the glenoid cavity of the scapula, and 32 inches (81.28 cm) was the length of the forelimbs measured from the olecranon to the heel. Additional measurements showed that the length from elbow to knee was 28 inches (71.12 centimeters) and the knee girth was 24 inches (60.96 centimeters). Specific measurements were obtained in the forefoot. The nails on

the left side measured 3.65 by 5 inches (9.207 by 12.7 centimeters), the nails on the middle side measured 3.5 by 7.5 inches (8.89 by 19.05 centimeters), and the nails on the middle side measured 5.5 by 3.85 inches (14.02 by 9.805 centimeters). A measurement of the footpad revealed dimensions of 9.8 by 8.8 inches (22.86 by 22.35 cm). Furthermore, the forefoot's circumference at the coronet level was measured to be 29.2 inches (74.168 cm). These measurements are important for understanding the anatomy and physiology of the forelimbs and forefeet which in turn can be used to assess the health and condition of the animal and provide the necessary healthcare on time.

Hindquarters

The penis measured 34 inches, or 86.36 cm, in length. The measurements revealed that the distance measured was 44 inches (111.76 cm) from the hip to the heel, 12 inches (30.48 cm) from the hock to the heel, 18 inches (45.72 cm) from the hock to the fetlock, and 40 inches (101.6 cm) from the groin to the heel. The groin width measured was 34 inches, or 86.36 cm. Proceeding to the rear foot. The dimensions of the lateral nail on the hind foot were 4.16 by 11.18 by 5.08 cm, or 4 by 4.4 by 2 inches. The central nail measured 4 by 5 inches (10.16 cm × 12.7 cm), while the medial nail measured 4 by 4.3 inches (10.16 cm). The measurements of the hind foot were as follows: the footpad measured 8.8 inches by 7.2 inches (22.35 cm by 18.29 cm), the hind foot measured 11 inches by 9 inches (27.94 cm by 22.86 cm), and the circumference of the hind foot at the coronet was 26.7 inches (67.82 cm).

Skin Thickness

The following skin thickness measurements were made: A thickness of 1.9 cm (0.75 inches) at the thigh. Approaching the groin area, the thickness was 1.27 centimeters (0.5 inches), and 1.8 centimeters (0.7 inches) above the semimembranosus muscle. It is crucial to remember that these measurements show the skin's thickness at a particular point in time. The age, weight, and degree of activity of the person are only a few of the variables that might cause changes in skin thickness over time.

Abdominal Measurements/Abdominal Fat Thickness

The thickness of the abdomen fat was measured and found to be 3.1 inches (7.87 cm). The thoracic region's muscular breadth was determined to be 2 inches (5.08 cm). Shifting to the dimensions of the abdomen and thorax, the ventral measurements showed that the abdominal width was 40 inches (101.6 cm) and the thoracic width was 30 inches (76.2 cm). The length measured 42 inches (106.68 cm) from the base of the penis to the sternum. Our comprehension of the physical characteristics of rhinoceroses is enhanced by these measurements.

Head

The skull's ventral length was 28 inches (71.12 cm). The skull's lateral length measured more than 27 inches, or 68.58 cm. The measurement of the intermandibular distance was 17 inches, or 43.18 cm. The ear was 11 inches by 6 inches (27.94 cm by 15.24 cm), while the length of the nostril was 4 inches (10.16 cm).

Organs

Regarding the dimensions of the liver, the left lobe measured 21 by 15 centimeters (8.3 by 5.9 inches), whereas the right lobe was 39 by 51 centimeters (15.4 by 20.1 inches). The liver's total length was 74.3 centimeters (29.2 inches), of which 13 by 17 centimeters (5.1 by 6.7 inches) was the extension of the middle lobe. The heart's measurements were 48 centimeters wide (19 inches), 53 centimeters long (21 inches), and 5 centimeters thick (2 inches) in the left ventricle. The aorta measured 10 centimeters (4 inches) in diameter. The measurements taken for each of the lungs are as follows: the right lung measured 93 centimeters (36.6 inches) in length and 53 centimeters (20.9 inches) in width. In the meantime, the left lung measured 49 centimeters (19.3 inches) in width and 91 centimeters (35.8 inches) in length. The trachea, an essential organ of the respiratory system, measured 7 centimeters (2.8 inches) in diameter at its bifurcation. Moving on to the spleen, these were its important dimensions: The length was 129 centimeters (51 inches), while the measurement of the breadth was 43 centimeters (17 inches).

DISCUSSION

Necropsy may be the only way to identify an animal's cause of death in certain cases, particularly in cases where the animal is discovered dead without any noticeable symptoms. As a result, necropsy continues to be a valuable instrument for examining health issues, particularly those involving developing illnesses. Necropsies are typically performed on animals that have recently passed away [15]. In this study, we have demonstrated the information taken from necropsy reports and its possible utility for rhinoceros health surveillance. The rhino's forelimbs, forefeet, hind limbs, and hind feet morphometric measures yielded important details on the anatomy and physiology of the animal that can be utilized to evaluate the animal's state of health. Furthermore, understanding the fundamental morphometric parameters of reproductive organs, like penis length, is undoubtedly helpful in determining breeding soundness and possible fertility in male breeding [16]. When assessing breeding soundness and potential fertility in breeding males, knowledge of the basic morphometric parameters of reproductive organs is quite valuable [17,18]. The thickness of the abdominal fat, the

thoracic muscle width, the ventral abdominal width, the thoracic width, and the distance between the sternum and the base of the penis were all measured in this study on the physical characteristics of rhinoceroses. Additionally, the thickness of the skin at several thigh areas was measured. Our comprehension of the physical characteristics of rhinoceroses is enhanced by these measurements. Many morphological and physiological parameters vary in different wild animals' species and to investigate these variations, the animal was measured extensively [14,19]. The diameters of several organs were documented in this study on the physical characteristics of rhinoceroses. The inter-mandibular distance was notable, and the skull had both ventral and lateral lengths. The dimensions of the ear were depicted, highlighting the complex geometry of this sense organ. The measures of the left and right lobes of the liver were shown. The liver's total length was influenced by the middle lobe's extension. Measurements were made of the left ventricle thickness, breadth, and length of the heart. Additionally, the aorta's diameter was given. It was also mentioned how big the left and right lungs were. The trachea displayed a diameter where it split. The width and length of the spleen were measured. Biometry of the different organs and body parts can be utilized to determine the age and weight in order to allow a better understanding of the health of the wild otherwise unapproachable animals [20,21]. These metrics establish the vitality of these important organs. Future studies on the physiology and anatomy of the animal may benefit from these findings.

CONCLUSIONS

This study sheds light on the right anatomical characteristics giving notable insight into the unique species' extensive biometry contributing significantly to future efforts in the conservation of the endangered species further contributing to the captive breeding, forensic applications and lastly essential veterinary care including the correct evaluation of the animal's health so that the necessary attention required to the animals with any underlying condition can be given in the correct time frame. Since this sort of study has not been published before, it could prove essential to the future research efforts that focus particularly on the Indian One Horned Rhinoceros.

Authors Contribution

Conceptualization: MRK, BNK, RF

Methodology: ZU, AM

Formal Analysis: FN

Writing-review and editing: MR, MA, AM, RF

All authors have read and agreed to the published version of the manuscript.

Conflicts of Interest

The authors declare no conflict of interest.

Source of Funding

The authors received no financial support for the research, authorship and/or publication of this article.

REFERENCES

- [1] Subedi N, Jnawali SR, Dhakal M, Pradhan NM, Lamichhane BR, Malla S et al. Population status, structure and distribution of the greater one-horned rhinoceros *Rhinoceros unicornis* in Nepal. *Oryx*. 2013 Jul; 47(3): 352-60. doi: 10.1017/S0030605313000562.
- [2] Zschokke S and Baur B. Inbreeding, outbreeding, infant growth, and size dimorphism in captive Indian rhinoceros (*Rhinoceros unicornis*). *Canadian Journal of Zoology*. 2002 Nov; 80(11): 2014-23. doi: 10.1139/z02-183.
- [3] Mukherjee T, Sharma LK, Saha GK, Thakur M, Chandra K. Past, present and future: combining habitat suitability and future landcover simulation for long-term conservation management of Indian rhino. *Scientific Reports*. 2020 Jan; 10(1): 606. doi: 10.1038/s41598-020-57547-0.
- [4] Amin R, Thomas K, Emslie RH, Foose TJ, Strien NV. An overview of the conservation status of and threats to rhinoceros species in the wild. *International Zoo Yearbook*. 2006 Jul; 40(1): 96-117. doi: 10.1111/j.1748-1090.2006.00096.x.
- [5] Dinerstein E. *The Return of the Unicorns: The Natural History and Conservation of the Greater One-Horned Rhinoceros*. New York Chichester, West Sussex: Columbia University Press; 2003. doi: 10.7312/dine08450.
- [6] Heidegger EM, von Houwald F, Steck B, Clauss M. Body condition scoring system for greater one-horned rhino (*Rhinoceros unicornis*): Development and application. *Zoo Biology*. 2016 Sep; 35(5): 432-43. doi: 10.1002/zoo.21307.
- [7] Biknevicius AR. Biomechanical scaling of limb bones and differential limb use in caviomorph rodents. *Journal of Mammalogy*. 1993 Feb; 74(1): 95-107. doi: 10.2307/1381908.
- [8] Adhikari BP, Haider W, Gurung O, Poudyal M, Beardmore B, Knowler D et al. Economic incentives and poaching of the one-horned Indian rhinoceros in Nepal stakeholder perspectives in biodiversity conservation: analysis of local, national and global stakes in rhino conservation in Royal Chitwan National Park, Nepal. *SSRN Products and Services*. 2005.
- [9] Albarella U. 'Size matters': how and why biometry is still important in zooarchaeology. In: Dobney K and O'Connor T, (eds.). *Bones and the Man: Studies in honour of Don Brothwell*. Oxbow Books, Oxford. 2002: 51-62.
- [10] Ghosh T, Kumar S, Sharma K, Kakati P, Sharma A, Mondol S. Consideration of genetic variation and evolutionary history in future conservation of Indian one-horned rhinoceros (*Rhinoceros unicornis*). *BMC Ecology and Evolution*. 2022 Jul; 22(1): 92. doi: 10.1186/s12862-022-02045-2.
- [11] McGavin MD and Zachary JF. *Pathologic basis of veterinary disease*. Elsevier Health Sciences; 2006 Aug.
- [12] Rech RR, Giaretta PR, Ploeg R, Edwards EE, Brown CC, Barros CS. Shapes of pathology. *Pesquisa Veterinária Brasileira*. 2021 Jul; 41:e06894. doi: 10.1590/1678-5150-pvb-6894.
- [13] Christiansen P. Mass allometry of the appendicular skeleton in terrestrial mammals. *Journal of Morphology*. 2002 Feb; 251(2): 195-209. doi: 10.1002/jmor.1083.
- [14] Campione NE and Evans DC. A universal scaling relationship between body mass and proximal limb bone dimensions in quadrupedal terrestrial tetrapods. *BMC Biology*. 2012 Dec; 10: 1-22. doi: 10.1186/1741-7007-10-60.
- [15] Nietfeld JC. Field necropsy techniques and proper specimen submission for investigation of emerging infectious diseases of food animals. *The Veterinary Clinics of North America. Food Animal Practice*. 2010 Mar; 26(1): 1-3. doi: 10.1016/j.cvfa.2009.10.005.
- [16] Cubo J and Casinos A. The variation of the cross-sectional shape in the long bones of birds and mammals. In *Annales des Sciences Naturelles-Zoologie et Biologie Animale*. 1998 Jan; 19(1): 51-62. doi: 10.1016/S0003-4339(98)80134-2.
- [17] Ibrahim AA, Aliyu J, Ashiru RM, Jamilu M, Ibrahim A, Aliyu J et al. Biometric study of the reproductive organs of three breeds of sheep in Nigeria. *International Journal of Morphology*. 2012 Dec; 30(4): 1597-603. doi: 10.4067/S0717-95022012000400053.
- [18] Schmidt M and Fischer MS. Morphological integration in mammalian limb proportions: dissociation between function and development. *Evolution*. 2009 Mar; 63(3): 749-66. doi: 10.1111/j.1558-5646.2008.00583.x.

- [19] Kettle BT and Lucas JS. Biometric relationships between organ indices, fecundity, oxygen consumption and body size in *Acanthaster planci* (L.) (Echinodermata; Asteroidea). Bulletin of Marine Science. 1987 Sep; 41(2): 541-51.
- [20] Kouamo J, Saague AM, Zoli AP. Determination of age and weight of bovine fetus (*Bos indicus*) by biometry. Journal of Livestock Science. 2018 Jan; 9.
- [21] Dayan MO, Beşoluk K, Eken E, Aydoğdu S, Turgut N. Three-dimensional modelling of the femur and humerus in adult male guinea pigs (guinea pig) with computed tomography and some biometric measurement values. Folia Morphologica. 2019; 78(3): 588-94. doi: 10.5603/FM.a2019.0002.