



MARKHOR

THE JOURNAL OF ZOOLOGY

<https://www.markhorjournal.com/index.php/mjz>
ISSN (P): 2790-4377, (E): 2790-4385
Volume 5, Issue 1 (Jan-Mar 2024)



Original Article

Incidence of Cestode Parasites and Assessment of Histopathological Alterations in the Intestine of Domestic Pigeons (*Columba livia domestica*) in District Hyderabad, Sindh, Pakistan

Bakhtawar Soomro^{1*}, Shakeel Ahmed Memon¹, Sajida Mushtaq² and Sadia Malik²

¹Department of Zoology, Government College University, Hyderabad, Pakistan

²Department of Zoology, Government College Women University, Sialkot, Pakistan

ARTICLE INFO

Keywords:

Helminths, Cestode Parasites, Histological Alterations, *Columba Livia domestica*

How to cite:

Soomro, B., Memon, S. A., Mushtaq, S., & Malik, S. (2024). Incidence of Cestode Parasites and Assessment of Histopathological Alterations in the Intestine of Domestic Pigeons (*Columba livia domestica*) in District Hyderabad, Sindh, Pakistan: Cestode Parasites in Domestic Pigeons. MARKHOR (The Journal of Zoology), 5(01). <https://doi.org/10.54393/mjz.v5i01.91>

*Corresponding Author:

Bakhtawar Soomro
Department of Zoology, Government College University, Hyderabad, Pakistan
bakhtawarsoomro145@gmail.com

Received Date: 7th February, 2024

Acceptance Date: 23rd March, 2024

Published Date: 31st March, 2024

ABSTRACT

The avian species are severely harmed by helminth parasites. Many of the parasites infected them via habitats, feeding habits, or by a few infected birds that coexist with them. **Objective:** To examine histological alterations caused by cestode parasites in the pigeon's intestines in the district of Hyderabad, Sindh, Pakistan. **Methods:** One hundred (100) domestic pigeons (*Columba Livia domestica*) were used after that pigeons were dissected and their intestines were excised. Under the dissecting microscope and magnifying glass various parts of the intestine were examined to see the presence of the cestode parasites. The (H & E) staining method was applied for histological study. **Results:** The cestode parasites that infected the pigeons were identified as *Choanotenia infundibulum*, *Raillietina cesticillus*, and *Cotugnia digonopora*. Infected Pigeons had diarrhea, weakness, emaciation, and stunted development. Histopathological alterations in the intestine of pigeons caused by *Cotugnia digonopora* have disfigured the villus and glands. The intestinal architecture was destroyed, villi degraded, the muscle layer had holes, and glands were distorted by *Raillietina cesticillus* and *Choanotenia infundibulum*, respectively. **Conclusions:** This research revealed that the pigeon's intestine was infected with cestode parasites and had notable histological alterations as compared to non-infected pigeons. It is concluded that this study will help out in the documentation of specific parasite species and also provide a valuable understanding of the pathogenesis of infections in birds.

INTRODUCTION

Birds are susceptible to various diseases due to their scavenging behavior, with gastrointestinal parasite infections being particularly common [1]. These illnesses can worsen and cause significant losses [2]. Parasites are protozoans that live inside or on the host's body. Examples of gastrointestinal parasites that can infect birds are helminth parasites like cestodes, in particular, are the most significant category of helminth parasites in terms of the variety of species they infect and the harm they cause [3]. The pigeons are kept for sport, as pets, and as a vital source of food throughout the world [4]. Gastrointestinal parasitic infections are the most prevalent in birds, which has an

overwhelming effect on productivity [5]. Parasitic infections in poultry birds have been reported from various parts of the world, including Pakistan [6-8]. Birds have significant nutritional value as well as socioeconomic benefits that cannot be overstated [9]. The domestic pigeon (*Columba livia domestica*) is an important member of the avifauna and can be found practically everywhere in the world [10]. Worldwide Pigeon populations are thought to range from 180 to 350 million. Different species of helminth parasites can cause histopathological lesions that include catarrhal alterations, degeneration, and desquamation of epithelial cells, hemorrhagic, nodular,

and fibrino-necrotic enteritis, and hyperplastic changes [11, 12]. The feral pigeon and domestic pigeons may be a possible source of many human diseases and can also transmit parasitic diseases to new animals and other poultry birds [13]. Domestic pigeons are an essential source of protein for individuals as they gain weight faster than other birds, are easy to breed, and can be infected with a wide variety of parasitic diseases. The proximity of pigeons to other poultry increases the risk of chickens becoming infected with parasites. Cestodes require at least one intermediate host before they can complete their life cycle in birds [14]. These worms can cause eating disorders, weight loss, and diarrhea. Infection can be diagnosed by looking for eggs or sometimes proglottids in the stool [15]. Copious research work has been carried out on the histology of diverse groups of different bird species [16, 17]. Experimental studies also revealed histopathological variations in pigeons suffering from New Castle disease [18]. Histopathological deviations in the intestine of female lesser flamingos infected with multiple cestodes [19].

The purpose of this study was to determine the proportions and severity of cestode infection in domestic pigeons (*Columba Livia domestica*). So that researchers and veterinarians might create focused remedies to reduce the effects of parasitic diseases on pigeon populations by clarifying the processes behind these changes, it is imperative to banquet the knowledge and data about the significance of preventative measures like routine deworming and hygienic practices.

METHODS

The present study was carried out following approved protocol at the Department of Zoology, Government College University Hyderabad, Sindh, and Pakistan. The objective of the study was to evaluate parasitic infection caused by cestode parasites [20, 21]. A total of 100 live Pigeons (*Columba livia domestica*) were brought from various crop fields and villages of Hyderabad, Sindh, Pakistan. The pigeons were then transported to the laboratory for further research analysis. Pigeons were then dissected and their intestines were excised. The various intestinal sections were carefully removed from the pigeons's body cavity and placed in petri dishes with normal saline the dissecting microscope and magnifying glass were used to examine various parts of the intestine and search for the cestode parasites. The pigeons' non-infected intestine was also examined by the same method. Before fixation, the parasites were left to be relaxed, which was accomplished by immersing them in saline water for around 20–30 minutes or by slowly adding drops of 70% alcohol. The parasites were killed and then placed in jars with 70% alcohol to preserve them. The cestodes were

pressed between two plain glass slides, fastening them with thread, and providing sufficient pressure before they were passed through the graded series of alcohol. After that, the slides were submerged for 24 to 48 hours in 70% alcohol. Thereafter, stained with Borax carmine and washed away by using an alcohol-graded series for complete dehydration. The stained cestodes were passed through clove oil and cleared in xylene. They were mounted in Canada balsam. The key and available literature used for cestodes was identification [22, 23]. The intestinal pieces were fixed in the Bouin's fluid. Likewise, uninfected intestinal pieces were also fixed in Bouin's solution. The preserved pieces of intestine from Bouin's fluid were separated and washed in running tap water. Thereafter, these were dehydrated with graded alcohol series, clarified in xylene, and embedded in paraffin wax. After section cutting was carried out with a Rotary Microtome machine and the thickness of the sections (6 microns) was regulated by the adjustment of the indicator. The best section slides were stained with (H & E) stain. Moreover, microphotography and histological examination were carried out by using the Best Scope LCD digital biological LCD microscope BLM 260. Finally, the stained sections were mounted in Canada balsam and examined under a microscope. The results were analyzed statistically by applying the statistical program using the ANOVA for P-values significance.

RESULTS

The pigeon's normal intestine is a multilayered tube made up of two muscle layers: one circular and the other longitudinal. The intestine's front surface is complexly folded into many assemblies known as villi, which significantly increase its exterior area that is absorbent. Lieberkühn's crypts are among the villi; they contain crypt cells that move up the villi and divide into the main goblet cells. Along the length of the villi, absorptive epithelial cells are most abundant, whereas goblet cells are sporadically scattered (Figure 1)

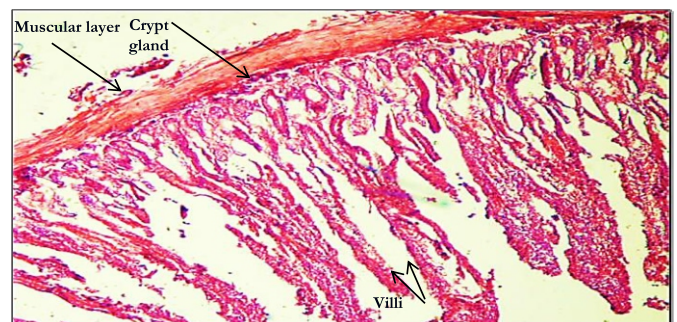


Figure 1: The Histological Section Showing Over The Normal Structure Of The Intestine Including The Muscular Layer Crypt Glands And Villi X 100 (no full stops after captions in tables/figures unless a statement that is

necessary. If not necessary modify the caption a bit) Domestic pigeons' intestinal tracts harboring cestode parasites exhibit a variety of histological changes that impact both the mucosal and submucosal layers. These changes fall into many categories and are often indicative of the host-parasite interaction and the cestode parasite species identified are shown in table 1.

Table 1: Number Pigeons Infected and Non-Infected Pigeons along with Cestode Parasites Species Recovered from the Intestine of Infected Pigeons and their Intensity

Parasites	Parasites Species	Infected out of 100 Pigeons	Intensity of Parasites	Non-Infected out of 100 Pigeons
Cestodes	<i>Raillietina cesticillus</i>	55	4-8	45
	<i>Choanotaenia infundibulum</i>	44	2-4	56
	<i>Cotugnia digonopora</i>	40	1-3	60

It has been observed that the 100 specimens of the pigeon showing multi infections or co infections to be infected 55 with *Raillietina cesticillu*, 44 with *Choanotaenia infundibulum* and 40 with *Cotugnia digonopora*. An examination of the intestine of a pigeon infected by *Cotugnia digonopora* parasite showed significant tissue damage. There were many regions containing the pigeons' infected intestine, which displayed a total loss of the intestine's normal structure. The most frequent side effects were inflammation, muscle layer injury, and hyperplasia of the crypto glands. The histological examination of the intestine of an infected pigeon caused by *Cotugnia digonopora* revealed complete alteration and distortion of villi and glands with destruction and loss of the normal articulation and dislocation of muscle layers (Figure 2).

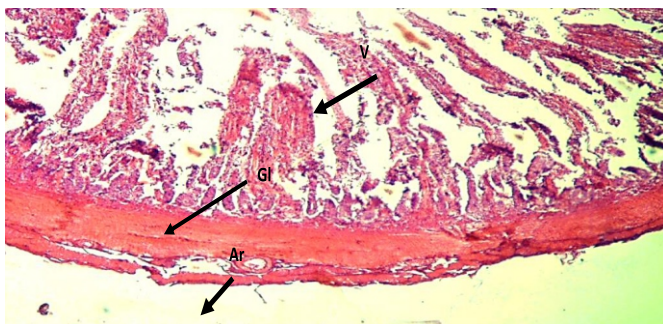


Figure 2: Histopathological Section of Infected Intestine Caused *Cotugnia Digonopora* of Pigeons showing Breakdown of Villi, Crypt Glands the Muscle Layer an Indistinct Artery is Obvious X50

According to the histological results, the *Raillietna Cesticillus* infection was harmful to the whole intestinal architecture, including the glands and muscle layers known as villi. In some areas, the structure of the villi was completely altered and rendered undetectable, with a massive mass of cells in place of the villi, glands distorted, and the muscle layer vacuolated. The intestinal layer of the

parasite is shown in (Figure 3) where the fusion of glands and destruction of the villi are visible. Villi were demolished and there was a significant infiltration of plasma cells into the mucosal layer. Atrophied muscle layers with squeezed vacuolation were seen in some sections.

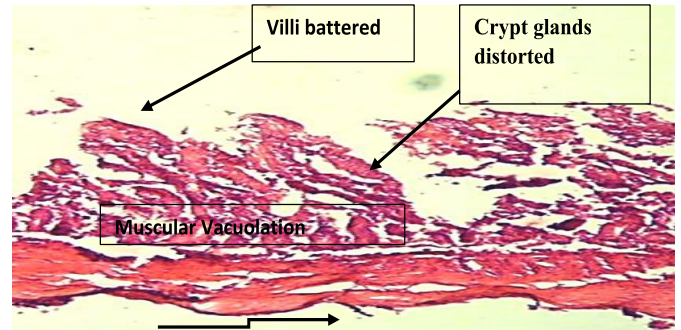


Figure 3: The histological section of the intestine of the infected pigeon caused by *Raillietina cesticillus* parasite showing the destruction of the architecture of the intestine, battered villi, and vacuolations in the muscular layer X50

Sections of the infected intestine of pigeons caused by cestode *choanotenia infundibulum* serve as the basis for histological studies. The histological examinations showed that the architecture of the gland, villi, and muscle layers had been destroyed, distorted, fused, and inflamed. It was often seen that the architecture of glands was being destroyed. In some sections, the lumen of the crypt glands was shown to be entirely closed, while in others, the glands joined to create an indistinguishable structure. There was evidence of inflammation in this region. At the base of the crypts, lamina propria were seen to be necrotic. The muscle layer displayed voids created by the separation of fibers as a result of shrinking. This layer's blood vessel also displayed structural distortion (Figure 4).

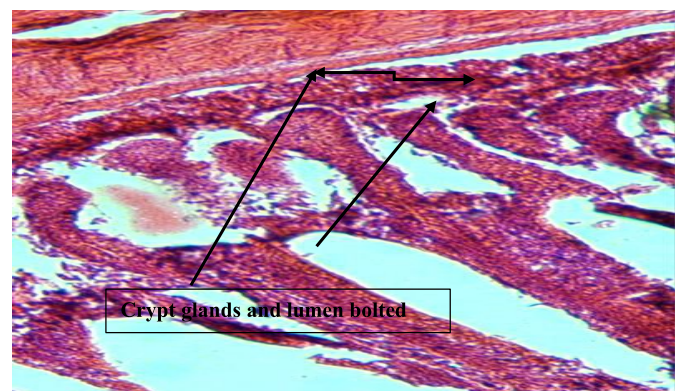


Figure 4: Histological Section of Intestine of Infected Pigeons by *Choanotenia Infundibulum* Parasite Showing Crypt Glands and Lumen of the Glands Is Bolted X100

The histopathological changes caused by cestode parasites in the intestine of domestic pigeons have also provided important insights into the research of

pathophysiology and histopathological diseases in addition to helping identify certain parasite species.

DISCUSSION

Domestic pigeons are an important part of community economies worldwide, and they are also considered an additional source of meat and eggs. However, the production of racing pigeons is hampered by the prevalence of parasitic infections, such as cestode parasites, which cause significant health problems for pigeons. The intestine is the main host of cestode parasites, so the study of histological changes in the infected intestine can be key to detecting cestode infection in domestic pigeons. The results of our study were consistent with the published findings the intestines of infected pigeons were clogged due to helminthiasis. Examinations of the infected intestine showed severe tissue destruction. The infected intestine of the pigeons, which showed a complete loss of the normal structure of the intestine, was found in several sections. The most common consequences were hyperplasia of the crypto glands, inflammation, and damage to the muscle layer. Villi in the mucus layer were seriously injured. The crypt gland showed the distortion and hyperplasia shown by *Cotugnia digonopora*. Although some studies have reported the presence of parasites using genetic approaches, some studies have looked at histopathological changes in the intestine of infected pigeons as an important diagnostic tool to confirm cestode infection. Among the several histopathological changes observed in the intestine of infected pigeons were atrophy and deformation of vesicles and glands accompanied by erosion, loss of typical intestinal architecture, infiltration of inflammatory lymphocytes, increased intestinal mucosal necrosis, and mucosal stratification epithelium in the lumen. The histological changes observed in our study were consistent with previously described histopathological changes caused by cestodes [24]. Other histopathological changes observed in our study included architectural collapse of the muscle layer, destruction of Brunner's and crypto glands, necrosis of the serous layer, formation of migrating tunnels with fibrosis, villous atrophy, and lamina propria infiltration mononuclear cells (macrophages and lymphocytes). Moreover, the results of our study on histopathological changes are consistent with those previously reported in the intestine of domestic chickens from Iraq and Egyptian domestic pigeons which had the cestode *Cotugnia sp.* Infection [25, 26]. Histological findings showed that *Raillietna Cesticillus* with severe infection was harmful and

affected the entire intestinal architecture, including the bladders and glands of the muscle layers. In certain sections, the structure of the villi was completely altered and unrecognizable, revealing a large cell mass, glandular distortion, and vacuolation of the muscle layer instead of the villi (Figure 3). This was in line with the results of Shaikh et al., who found higher changes than earlier reported results reported by Butt et al., and by Medjouel et al [27-29]. Histological studies are based on intestinal sections of pigeons infected with the cestode *Choanotenia infundibulum* [25, 26]. Histological studies showed distortion, melting, inflammation, and destruction of muscle layers, villi, and glandular architecture (Figure; 4). Degeneration of glandular architecture was regularly observed. The crypto glands were joined to create an unknown structure (Figure 4). These changes higher were than those reported by Medjouel et al., in Ethiopia and in Iran Eslami et al [29, 30].

CONCLUSIONS

The many histological changes they caused in the intestine by cestode parasites signify a serious risk to the well-being and health of domestic pigeons. Researchers and veterinarians may create focused therapies to lessen the effects of parasite diseases on pigeon populations by clarifying the processes behind these changes. To further protect the health of these cherished bird friends, it is imperative to spread knowledge about the significance of preventative measures like routine deworming and hygienic practices.

Acknowledgments

The authors express gratitude to the Department of Zoology at Government College, University, Hyderabad, Sindh, Pakistan for providing the necessary laboratory facilities.

Authors Contribution

Conceptualization: BS, SAM, SM¹, SM²

Methodology: BS, SAM, SM, SM

Formal analysis: BS, SAM, SM, SM

Writing, review and editing: BS, SAM, SM, SM

All authors have read and agreed to the published version of the manuscript.

Conflicts of Interest

The authors declare no conflict of interest.

Source of Funding

The author received no financial support for the research, authorship and/or publication of this article.

REFERENCES

- [1] Ashenafi H and Eshetu Y. Study on gastrointestinal helminths of local chickens in central Ethiopia. *Revue de Médecine Vétérinaire*. 2004; 10: 504-7.
- [2] Hassan SA. National poultry congress and exhibition-2004, Lahore; 9-10 April 2004.
- [3] Cabodevilla X, Aebischer JN, Mougeot F, Morales MB, Arroyo B, et al. Are population changes of endangered little bustards associated with releases of red-legged partridges for hunting? A large-scale study from central Spain. *European Journal of Wildlife Research*. 2020 Apr; 66(2): 1-10. doi: 10.1007/s10344-020-1366-3.
- [4] Alkharigy F, El Naas A, EL Maghrbi A. Survey of parasites in domestic pigeons (*Columba livia*) in Tripoli, Libya. *Open Veterinary Journal*. 2018 Oct; 8(4): 360-6. doi: 10.4314/ovj.v8i4.2.
- [5] Njunga GR. Ecto- and haemoparasites of chickens in Malawi with emphasis on the effects of the chicken louse, *Menacanthus cornutus*. Master's Thesis. The Royal Veterinary and Agricultural University, Denmark. 2003; 2.
- [6] Sayyed RS, Phulan MS, Bhatti WM, Pardeshi M, Shamsher Ali et al. Incidence of nematode parasites in commercial layers in Sawat. *Pakistan Veterinary Journal*. 2000; 20(2):107-8.
- [7] Mustafa K, Feride KS, Esmā KK, Hatice S.C. Prevalence of gastrointestinal helminthes in chickens in Afyonkarahisar district, Turkey. *Kafkas University Veterinary Faculty Journal*. 2009 Aug; 15(3): 411-6.
- [8] Dube SP, Zindi J, Mbanga, Dube C. A study of scavenging poultry gastrointestinal and ectoparasites in rural areas of Matebeleland province, Zimbabwe. *International Journal of Poultry Science*. 2010; 9(9): 911-5. doi: 10.3923/ijps.2010.911.915.
- [9] Matur BM, Dawam NN, Malann YD. Gastrointestinal helminth parasites of local and exotic chickens in Gwagwalada, Abuja (FCT), Nigeria. *New York Science Journal*. 2002; 3(5): 91-101.
- [10] Marques SMT, Dequadros RM, Da Silva CJ, Baldo M. Parasites of pigeons (*Columba livia*) in urban areas of Lages, Southern Brazil. *Parasitología Latinoamericana*. 2007 Dec; 62(3-4): 183-7. doi: 10.4067/S0717-77122007000200014.
- [11] Haag-Wackernagel and Bircher AJ. Ectoparasites from feral pigeons affecting humans. *Dermatology*. 2010 Dec; 220(1): 82-92. doi: 10.1159/000266039.
- [12] Anwar AH, Shamim H, Rana AH, Shah MN, Akhtar MZ. Pathology of cestode infection in indigenous and exotic layers. *Pakistan Journal of Agricultural Sciences*. 2000; 37: 1-2.
- [13] Ali M, Ibrahim R, Alahmadi S, Elshazly H. Ectoparasites and intestinal helminths of pigeons in Medina, Saudi Arabia. *The Journal of Parasitology*. 2020 Oct; 106(6): 721-9. doi: 10.1645/19-183.
- [14] Santos HM, Chen CC, Tsai CY, Hsish YC, Chung FC, Tyan YC, Tayo LL, Chuang KP. Influence of pigeon interferon alpha (PiIFN- α) on pigeon circovirus (PiCV) replication and cytokine expression in *Columba livia*. *Veterinary Microbiology*. 2020 Mar; 242: 108591. doi: 10.1016/j.vetmic.2020.108591.
- [15] Harrison GJ and Lightfoot TL. *Clinical Avian Medicine*, (Vol. 1, 2). Palm Beach, Florida: Sphinx Publishing Inc. 2006.
- [16] Riaz S, Alam SS, Ikram A. Histopathological changes observed in the heart and gizzard of quail chicks *Coturnix coturnix japonica* administered by the different levels of chrome shaving. *African Journal of Biotechnology*. 2006; 5(19): 1765-9.
- [17] Shaheen S, Anjum AD, Rizvi F. Clinicopathological observation of pigeons (*Columba livia*) suffering from newcastle disease. *Pakistan Veterinary Journal*. 2005 Jun; 25(1): 5-8.
- [18] Sarah L, Poynton, Mukherjee G, John D. Cestodiasis with intestinal diverticulosis in a lesser flamingo (*Phoeniconaias minor*). *Journal of Zoo and Wildlife Medicine*. 2000 Mar; 31(1): 96-99. doi: 10.1638/1042-7260(2000)031[0096:CWIDIA]2.0.CO;2.
- [19] Hayat B and Hayat CS. Incidence of intestinal parasites of chicken in Faisalabad district. *Pakistan Veterinary Journal*. 1983; 3: 165-7.
- [20] Permin A, Esmann JB, Hoj CH, Hove T, Mukaratirwa S. Ecto-endo and haemoparasites in scavenging chickens in the Goromonzi district, Zimbabwe. *Preventive Veterinary Medicine*. 2002 Jul; 54(3): 213-24. doi: 10.1016/S0167-5877(02)00024-7
- [21] Aini L. Indigenous chicken production in south Asia. *World's Poultry Science Journal*. 1990 Mar; 46: 51-7. doi: 10.1079/WPS19900010
- [22] Dharejo AM. Trematode parasites of birds of different feeding habits of Hyderabad District, Hyderabad, Sindh, Jamshoro, Pakistan. Ph.D. thesis, Faculty of Natural Sciences, University of Sindh, Jamshoro, Pakistan. 2006.
- [23] Shaikh F, Ursani TJ, Naz S, Dhiloo KH, Solangi AW. Histopathological Changes in the Intestine of Infected Pigeon (*Columba livia*). Naturally Infected with Helminth Parasites from Hyderabad, Sindh, Pakistan. *Science International (Lahore)*. 2016; 28: 5273-5.
- [24] Mahdi DS, Swadi BF, Thuwaini MM. Histopathological Changes in the Intestine of Domestic Chickens (*Gallus gallus domesticus*). Naturally Infected with

- the Cestode *Cotugnia* sp. in Basrah, Southern Iraq. *Biological and Applied Environmental Research*. 2018 May; 2: 12-21.
- [25] Ibrahim N, Hassan E, Moawad T, Ghobashy M. Morphological and Molecular Identification of Some Intestinal Helminths Infesting the Domestic Pigeon (*Columba livia domestica*) at Ismailia, Egypt. *Catrina: The International Journal of Environmental Sciences*. 2018 Sep; 17: 61-70. doi: 10.21608/cat.2018.14312
- [26] Kamal M, Khan W, Nisa NU, Yasmeeen G, Ul Hassan H, Ullah I. Acute Raillietiniasis in Domestic Pigeon (*Columba livia domestica*). *Advances in Animal and Veterinary Sciences*. 2020; 8: 1180-3. doi: 10.17582/journal.aavs/2020/8.11.1180.1183
- [27] Sheikh TS, Masood SM, Abdul RK. The prevalence and pathology of *Raillietina cesticillus* in indigenous chicken (*Gallus gallus domesticus*) in the temperate Himalayan region of Kashmir. *Veterinary Archives*. 2010 Mar; 80(2): 323-8.
- [28] Zubeda B, Shaikh AA, Khan MM. Prevalence and pathology of *Raillietina cesticillus* in the intestine of local chicken (*Gallus domesticus*) in Sindh. *Proceedings of Parasitology*. 2012; 53: 43-51.
- [29] Medjouel I and Benakhla A. Cestode parasites of chickens (*Gallus gallus domesticus*) in the North-Eastern of Algeria. *International Journal of Poultry Science*. 2013; 12(11): 681-4. doi: 10.3923/ijps.2013.681.684
- [30] Eslami A, Ghaemi P, Rahbari S. Parasitic infections of free range chickens from Golestan Province Iran. *Iranian Journal of Parasitology*. 2009; 4(3): 1-4.